



IRAQI
Academic Scientific Journals



العراقية
المجلات الأكاديمية العلمية

TJAS

Tikrit Journal for
Agricultural
Sciences

ISSN:1813-1646 (Print); 2664-0597 (Online)

Tikrit Journal for Agricultural Sciences

Journal Homepage: <http://www.tjas.org>

E-mail: tjas@tu.edu.iq

Immunohistochemical developmental comparative study between thymus and spleen of *Peacock(Pavo Cristatus)*

Ahmed Abdulla Hussein

Department of Anatomy and Histology/college of Veterinary Medicine/University of Diyala/Iraq

* Corresponding author: E-mail: Zainabubaidy151515@gmail.com

ABSTRACT

In thymus, CD8 showed -ve expression at one week age. At one and two months old, strongly +ve were observed within the thymic parenchyma and around Hassall's corpuscles. At seven months old, CD8 showed variable degrees of +ve expression especially around blood vessels but less frequency than that of the younger ages due to the retarded activity of the thymus gland. CD268 cells showed -ve expressions in cortex and medulla of thymus at the 1st week of age. At the age of one month old Peacock the CD268 exhibited high degree of +ve appearance for B cells. At the age of two months old, CD268 displayed +ve expression in thymic cortex particularly around the septae. At age of seven months old Peacocks, the adult cellular population were formed the whole parenchyma of thymus gland therefore CD268 give slightly +ve expression in the cortex mainly around the septae. While in the spleen, CD8 were showed -ve expression at the age of one week Peacock poult. At the age of (1,2 and 7) months old spleen have great role in the immunity. CD268 indicated -ve expressions at one week of age, because of most of the cells at this age immatured. Few numbers of B lymphocytes were showing +ve expression at one month of age. At age of two months old Peacock B cells showed highly +ve expression. At age of seven months old Peacocks showed +ve expression, and highly increase in the number of mature B lymphocytes compared with other previous younger ages.

KEY WORDS:

Immunohistochemical,
spleen, Development,
Thymus, CD268

Received: 19/09/2022

Accepted: 05/10/2022

Available online: 30/09/2023

© 2023 College of Agriculture, Tikrit University. This is an open access article under the CC by licenses <http://creativecommons.org/licenses/by/4.0>



دراسة كيميائية نسجية تطورية مقارنة بين الغدة الصعترية والطحال في الطاووس (*Pavo Cristatus*)

احمد عبد الله حسين

قسم التشريخ والانسجة ، كلية الطب البيطري ، جامعة ديالى، ديالى ، العراق

الخلاصة

في الغدة الصعترية ، أظهر CD8 تعبيرًا سالبًا في عمر أسبوع واحد. في عمر شهر وشهرين ، لوحظ تعبير موجب وبقوة داخل متن الغدة الصعترية وحول جسيمات هاسال. في عمر سبعة أشهر ، أظهر CD8 درجات متفاوتة من التعبير الموجب خاصة حول الأوعية الدموية ولكن أقل تواترًا من الأعمار الأصغر بسبب تأخر نشاط الغدة الصعترية. أظهرت خلايا CD268 تعبيرات سلبية في قشرة ولب الغدة الصعترية في عمر أسبوع واحد. في الطاووس الذي يبلغ من العمر شهرًا واحدًا ، أظهر CD268 درجة عالية من التعبير الموجب للخلايا البائية. في عمر شهرين ، أظهر CD268 تعبير موجب في قشرة الغدة الصعترية خاصة حول الحويصلات. في عمر سبعة أشهر من عمر الطاووس ، تشكل التجمعات الخلوية البالغة اغلب المتن للغدة الصعترية ، وبالتالي فإن CD268 يعطي تعبيرًا موجبًا طفيفًا في القشرة بشكل رئيسي حول الحويصلات.

بينما في الطحال ، CD8 أظهر تعبير سالب في عمر أسبوع واحد من عمر طائر الطاووس. في عمر شهر وشهرين وسبعة أشهر يكون للطحال دور كبير في المناعة. أظهر CD268 تعبير سالب في الأسبوع الأول من العمر ، لأن معظم الخلايا في هذا العمر كانت غير ناضجة. أظهر عدد قليل من الخلايا البائية تعبيرات موجبة في الشهر الأول من العمر. في عمر شهرين أظهرت خلايا البائية في الطاووس تعبير موجب عالي. في عمر سبعة أشهر ، أظهر الطاووس تعبيرات موجبة ، وزيادة كبيرة في عدد الخلايا البائية الناضجة مقارنة بالأعمار الأصغر السابقة الأخرى.

الكلمات المفتاحية: الكيمياء المناعية ، الطحال ، تطور ، الغدة الصعترية ، CD268.

INTRODUCTION

The lymphatic system is playing important role in immune responses, fluid homeostasis, absorption of fat, and is occupied in several pathological processes, such as metastasis of tumor cells and lymphedema. The considerate the origin and development of this system has been disadvantaged because of the lack of defining specific markers and difficulties in detecting its cells in vivo and execution genetic and experimental management of the lymphatic system. using of new specific markers, has begun to produce important visions into the development and association of this vital tissue (Butler *et al.*, (2009).

The Primary lymphoid tissue of birds is composed of organs responsible for the maturation of migrated stem cells into T and B lymphocytes progenitor's. The Secondary lymphoid tissue: complete the differentiation of T and B lymphocytes (Fath El-Bab, 2004). The chicken had both types of lymphatic organs: principal (thymus and bursa of Fabricius) and marginal (spleen and all mucosa associated lymphoid tissue) (Getty, 1975).

This study aimed to explained the Immunohistochemical developmental comparative study between thymus and spleen of *Peacock(Pavo Cristatus)*.

MATERIAL AND METHODS

Ten healthy Peacock poults at each of the subsequent ages (1 week, 1 month, 2 months and 7 months) old chose from a native farm in Iraq. The birds were kept in clean cages under firm hygienic conditions. The birds leaved for 14 days before euthanasia. All birds were euthanized by administration of over dose of sedatives (Xylazine 5mg per kg B.w) and Ketamine 15 mg per kg B.w)(Olfert, *et al* 2010). The birds were weighted then the spleen, thymus, were taken, after the birds were lying on their back and abdomen was opened. Lymphatic organs were quickly removed

and weighted after that washed with water and cut into small pieces and fixed in Neutral buffer formalin for 24 hrs for. Then Paraffin-embedded and sectioned at 5 μ m for Immunohistochemical studies by using polyclonal antibody to B-cell stimulation factor receptor(BAFFR) (CD268) produced in rabbit (cloud-clone corp. USA). Monoclonal antibody to T-cell (CD8) produced in mouse(info@antibodies-online.com).

RESULTS AND DESCUSSION

The thymus in Peacock

CD8 is a marker of choice for cytotoxic T cells and for T cells with suppressor activity. Clusters of Differentiation (CD8) were found on the surface of some natural killer cells. Some T-cells lymphocytes seemed to be faintly or toughly positive expression dependent on the age of development while other cellular elements were non-reactive. Positivity was characterized by brown staining of T cells cytoplasm. The Thymus gland observed slightly or strongly positive CD8 expression depend on the apoptotic activity and growth rate of the organ. CD8 showed -ve expression at one week of age (Fig1.A). At one and two months old, strongly +ve were observed within the thymic parenchyma and around Hassall's corpuscles (Fig.1.B,C). At seven months old, CD8 showed variable degrees of +ve expression especially around blood vessels but less frequency than that of the younger ages due to the retarded activity of the thymus gland (Fig.1.D). CD268 [polyclonal antibody to B-cell Stimulation Factor receptor (BAFFR)] is a marker of choice for the identification of mature B cells distributions within the thymus parenchyma. Expression is different among ages and even within same age, while the other cellular elements are non-reactive. Positivity was characterized by brown staining of mature B cell cytoplasm.

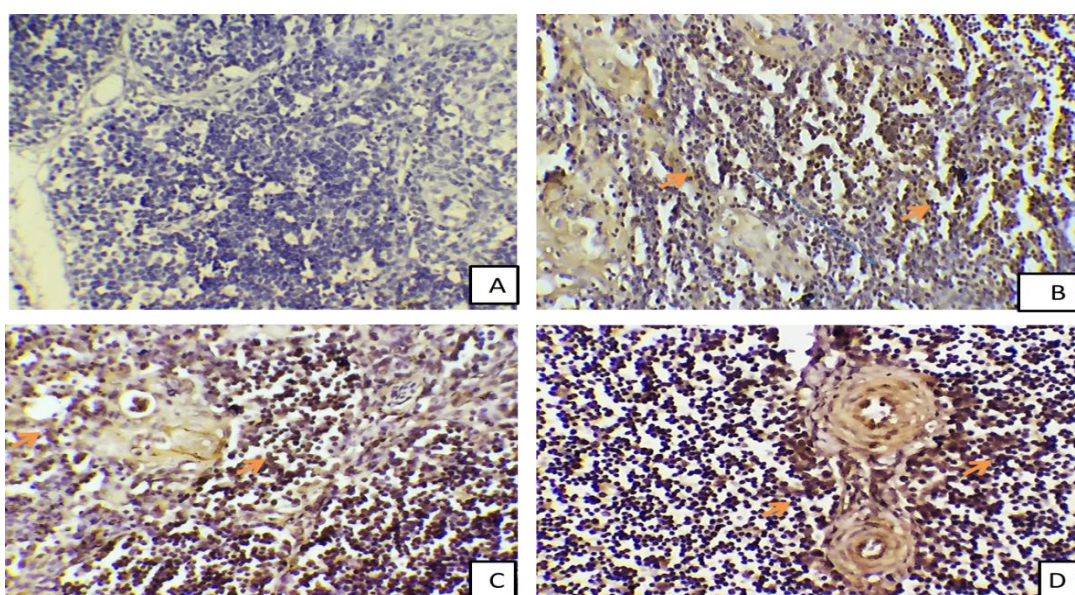


Fig.1, Immunohistochemical staining of a section of the thymus in Peacock shows the expression(arrows) of CD8 at (1 week(A),1 month(B),2 months(C)and 7 months (D). (Immunoperoxidase,40X)

CD268 cells showed -ve expressions in cortex and medulla of thymus at one week of age (Fig.2.A). At (1 month) old Peacock the CD268 showed high degree of +ve expression for B cells (brown staining) in the thymic medulla (Fig.2,B). At two months old, the CD268 showed +ve expression in thymic cortex particularly around the septae. There was a gradual increase in number of mature B lymphocytes with increase age (Fig.2.C). At age of seven months old Peacocks, the adult cellular population formed the whole parenchyma of thymus gland therefore CD268 give slightly +ve expression in the cortex mainly around the septae (Fig.2,D).

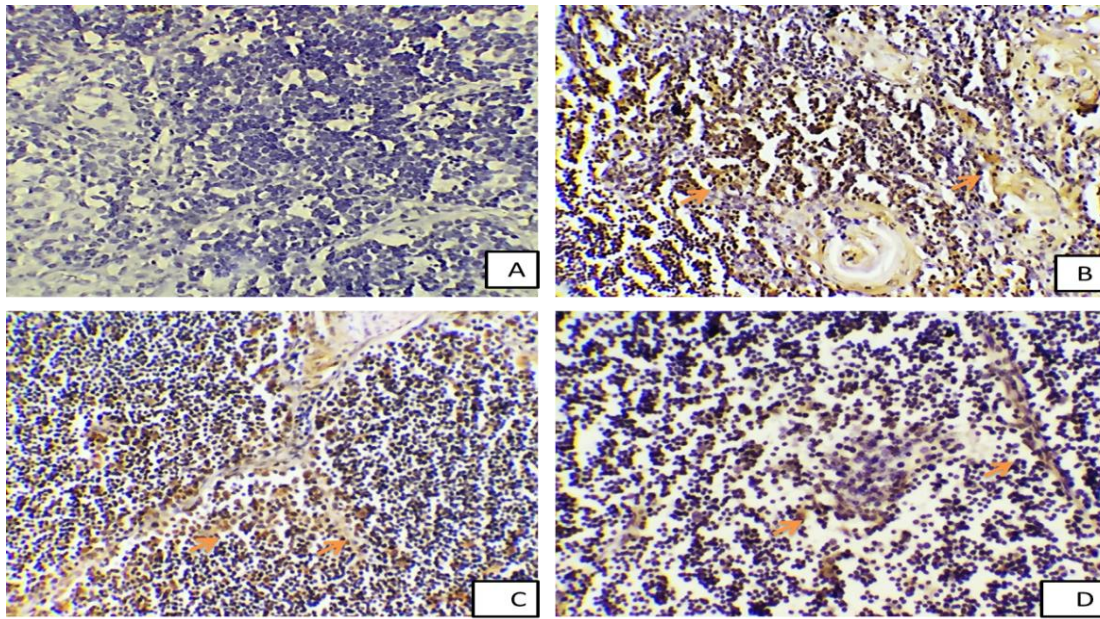


Fig2 Immunohistochemical staining of a section of the thymus in Peacock shows the expression(arrows) of CD268 at 1 week(A),1 month(B),2 months(C)and 7 months (D). (Immunoperoxidase,40X)

Immunohistochemical observation of the thymus cortex showed -ve CD8 expression at the age of one week old Peacock. This observation was incompatible with the observation of (Lowenthal *et al.*, 1993) who observed the T lymphocytes in chicken thymus was expressed immune reaction at one week post hatching. CD268 cells showed -ve expressions in the cortex and medulla of thymus at the age of one week old Peacock. This result was agreement with the result of Treesh *et al.*, 2014 who registered negative expression of B lymphocytes at the first three weeks of chicken age. The Peacock poult at age of one week depends on the maternal immunity, incomplete differentiation of thymus paranchyma in to cortex and medulla and most of the cells were immature. All these causes made the CD 8 and CD268 showed -ve expression. Immunohistochemical CD8 showed strongly + ve expression at one month old, within the thymic cortex and medulla due to the high activity of the thymus gland. This result was disagree with the result of Graczykn *et al.*, 2003 who registered that the intense maturation of T lymphocytes in chicken were happened in the cortex. The CD268 showed moderate degrees of +ve expression for B cells (brown staining) in both cortex and medulla. This observation was in agreement with the result of Abdul Masum *et al.*, 2014 who referred to the presence of high frequency of B cell positive expression in both cortex and medulla at the first month age of chicken. Treesh *et al.*, 2014 who observed the presence of moderate positive expression of B cells at age of one month old. The thymus have a vital role in the bird immunity in this age due to no maternal immunity, therefore, both T and B cells were present. At two months old, CD8 showed strongly + ve expression within the thymic cortex due to the high activity of the thymus gland. This result agrees with Graczykn *et al.*, 2003 who registered that the intense maturation of T lymphocytes in chicken were happened in the cortex. The medulla contain mature T lymphocytes mainly. CD268 showed +ve expression similar to that of one months. There was gradual increase in number of mature B cells with increase in age. This observation was in agreement with the result that found by Treesh *et al.*, 2014 who registered the presence of positive expression of B cells at the age after the fourth week in chicken thymus gland. From the first month post hatching until the age of maturity, the thymus takes its important immune role and the result of producing generations of mature lymphocytes that will turn into specialized immune cells. therefore, B cells showed positive expression. At seven months old, CD8 showed variable degrees of +ve expression but less frequency than that of the (one week, one month and two months), This observation was in compatible with the results that found by Akter *et al.*, 2006 and Aita, 2010 they observed the

presence of Immunocompetent T lymphocytes in the thymus lobule. At the age of sexual maturity(30 weeks), the thymus suffers from the decline of its activity. The adult cellular population were formed the whole parenchyma of thymus gland therefore CD268 give highly +ve expression. This result was in agreement with the result that found by Treesh *et al.*, 2014 and Akter *et al.*,2006 they registered the expression of B lymphocytes of chicken thymus cortex were denser than that of medulla at the advancing ages

The Spleen in Peacock

Some T-cell lymphocytes seemed to be slightly or strongly positive appearance dependent on the age of development while other cellular elements were non-reactive. Positivity was characterized by brown staining of T lymphocytes cytoplasm. CD8 were showed –ve expression at the age of one week Peacock poult because of the spleen has no role due to the bird yet depend on maternal immunity (Fig.3.A). At (1 month, 2 months and 7 months old the spleen have great role in the immunity there for the CD8 cells show in red pulp and around blood vessels were highly positive expression at these ages(Fig.3.B,C and D) respectively. CD268 showed –ve expressions at one week of age, because of most of the cells at this age were immature (Fig.4.A). Few numbers of B cells were showing +ve expression at one month of age (Fig.4.B). At age of two months old Peacock B cells showed highly +ve expression, there was an increase in number of mature B cells with increase in age (Fig.4.C). At age of seven months old Peacocks showed +ve expression, and highly increase in the number of mature B cells compared with other previous younger ages fig.4.D.

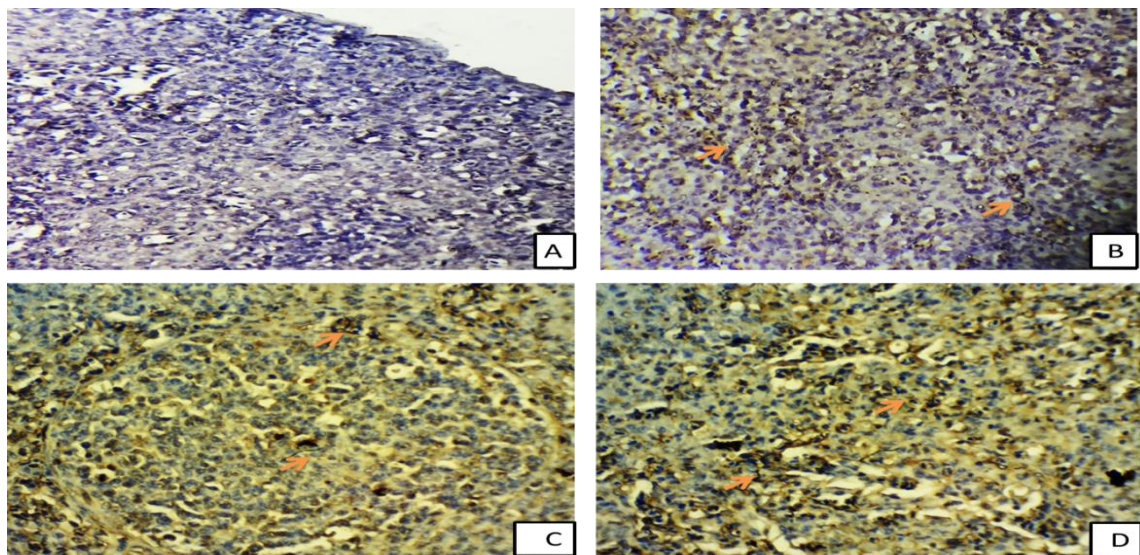


Fig.3 Immunohistochemical staining of a section of the spleen in Peacock shows the expression(arrows) of CD8 at 1 week(A),1 month(B),2 months(C)and 7 months (D). (Immunoperoxidase,40X)

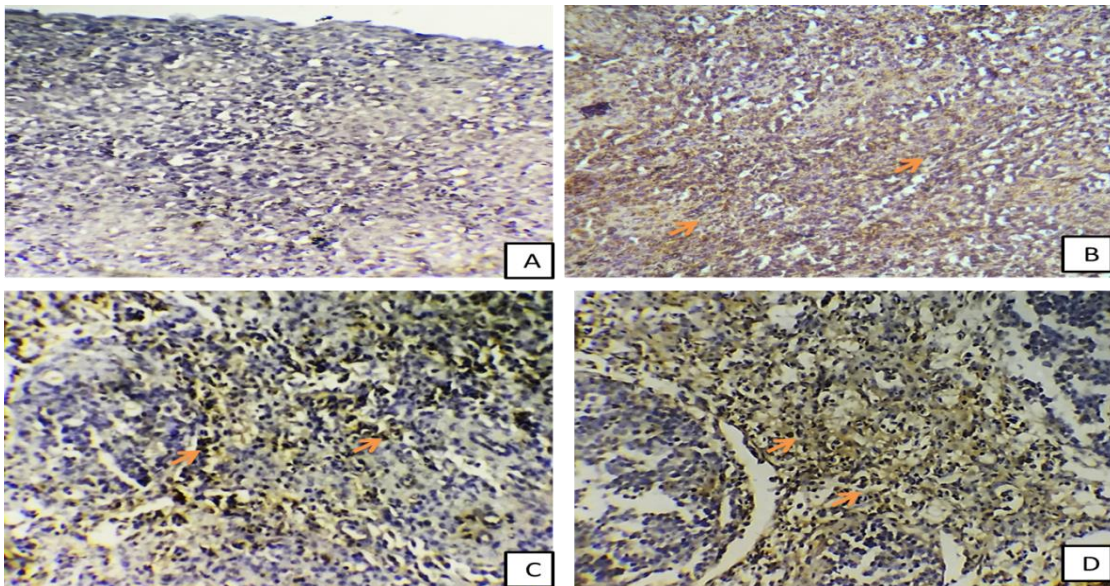


Fig.4.Immunohistochemical staining of a section of the spleen in Peacock shows the expression(arrows) of CD268 at 1 week(A),1 month(B),2 months(C)and 7 months (D).
(Immunoperoxidase,40X)

CD8 was showed -ve expression at the age of one week old Peacock poul. This result was in parallel with the observation of Hemmingsson, 1972 who observed that the T lymphocytes migration to spleen began at 9 day old chick. The spleen have no immunological role at one week old Peacock because of the bird was depended on maternal immunity. The immunological structure of spleen is completed after one week age. CD268 showed -ve expressions at one week of age. This result disagrees with that result found by Ogata *et al.*,1977 and Abdul Masum *et al.*2014 they found the presence of mature B cells in the parenchyma of chicken spleen at one week post hatching. In the current study of Peacock CD 268 responsible for expression of mature B cells, the majority of lymphocytes at this age were immature, therefore this marker was no expressed. The study suggest that the spleen at this age and a above was substituted the primary lymphoid organs. Therefore the CD8 T cell have a great role in apoptosis and normal development of spleen there for it presented in red and white pulp of spleen. The B lymphocytes showed +ve expression at the first month of age in white pulp, around trabeculae and central artery as well as periarterial lymphatic sheath. This result agree with Abdul Masum *et al.*2014 who registered the presence of mature B cells in the parenchyma of spleen at one month old chicken. At this age, few number of B lymphocytes were matured therefore, slight expression of CD268 marker were observed. At the age of two and seven months old Peacocks the CD268 showed +ve expression, and highly increase in the number of mature B cells in the peri arterial and peri venous lymphatic tissue. Quere *et al.*, 1990 in adult chicken noticed the same result. The study suggests that the activity of the secondary lymphoid organs increased when the primary lymphoid organs were entered the involution stage. The spleen was developed as substituted lymphoid organ

CONFLICT OF INTEREST

The authors declare no conflicts of interest associated with this manuscript.

REFERENCES

- Butler, M. G.; Isogai, S. and Weinstein B. M.(2009). Lymphatic Development. Birth. Defects Res. Embryo Today., 87(3): 222–231.
- Fath El-Bab, M. (2004). Histology of Birds. An Introductory Text for Veterinary Students. Second edition.: 15-20.

- Getty, R. (1975). Sission and Grossman's The Anatomy of the Domestic Animal. 5th edn., Vol. 2. W. B. Saunders Co., Philadelphia. London. pp. 2010-2018.
- Lowenthal, J. W.; Connick, T. E.; Mc Waters, P. G.; Obranovich, T. D. and York, J. J. (1993). Development of T cell immune responsiveness in young chicken. In: Avian Immunology in Progress. Condert, F. (Ed). France., 113-118.
- Treesh, S.A.; Buker, A.O. and Khair, N.S. (2014). Histological, histochemical and Immunohistochemical studies on thymus of chicken. 103-111.
- Graczyk, S.; Kuryszko, J. and Madej, J. (2003). Reactivity of Spleen Germinal Centres in Immunized and ACTH-treated Chickens. Acta. Vet. Brno.vol., 72: 523–531.
- Abdul Masum, M.D.; Khan, M. Z. I.; Nasrin, M.; Siddiqi, N. H.; Khan, M. Z. I. and Islam M. N. (2014). Detection of immunoglobulins containing plasma cells in the thymus, bursa of Fabricius and spleen of vaccinated broiler chickens with Newcastle disease virus vaccine. Int. J. of Vet. Sci. and Med., 2, 103–108.
- Akter, S. H.; Khan, M. Z. I.; Jahan, M. R.; Karim, M. R. and Islam, M. R.(2006). Histomorphological study of the lymphoid tissues of broiler chickens. Bangl. J. Vet. Med., 4 (2): 87–92.
- Hemmingsson, E. J. (1972). Ontogenic studies on lymphoid cell traffic in the chicken: III. Cell traffic from thymus. International Archives of Allergy and Applied Immunology., 43 (4): 487-496.
- Ogata, K.; Sugimura, M. and Kudo, N. (1977). Developmental studies on embryonic and posthatching spleen in chicken with special reference to development of white pulp. Japanese J. of Vet. Res., 25 (35): 83-92.
- Olfert ED, Cross BM, McWilliam AA, editors(2010). Canadian Council on Animal Care guide to the care and use of experimental animals, vol 1, 2'nd edition, chapter XII. *Euthanasia*.
- Quere, P.; Cooper, M. D. and Thorbecke, G. J. (1990). Characterization of suppressor T cells for antibody production by chicken spleen cells . Immunology, 71 (4): 517-522 .